



Fig. 1. von Kossa-stained slab section of hip cup implant.

Old Technology: The Foundation for Today's Cutting Edge Research

Robert A. Skinner HTL (ASCP), Research Coordinator
UAMS Center for Orthopaedic Research

William R. Hogue, Research Associate
UAMS Center for Orthopaedic Research

Charlene M. Flahiff, MS, Research Analyst
Duke University Department of Biomedical Engineering

Charles K. Lumpkin, Jr., PhD, Associate Professor
UAMS Department of Pediatrics

UAMS Center for Orthopaedic Research
University of Arkansas for Medical Sciences
4301 West Markham Street, Mail Slot 644
Little Rock, AR 72205
(501) 686-6292
skinnerroberta@uams.edu

Managing Editor: Gilles Lefebvre
Scientific Editor: Vinnie Della Speranza,
MS, HTL (ASCP) HT, MT

Abstract

A request to impart a color contrast to a bone/bone cement composite prosthesis was presented to the staff of the Center for Orthopaedic Research laboratory. The desired results were obtained by the modification of a century-old silver stain procedure which had been previously used in other laboratories for the morphometric analysis of mineralization patterns in sections of glycol methacrylate-embedded undecalcified bone.

Introduction

For several years, Dr. Carl Nelson, Chairman of Orthopaedics at the University of Arkansas for Medical Sciences, has been developing the concept of an implant consisting of a polymethyl methacrylate bone cement/allograft bone composite molded to the shape of a patient's acetabulum to be used in hip replacement surgery. In the "ball & socket" construct of the natural anatomy of the human hip joint, this portion of the implant acts as a "receiver" for the manufactured "socket" device. The theory was that

IN THIS ISSUE

Old Technology: The Foundation for Today's Cutting Edge Research	1
Paraffin Cleansing Demystified	4
Formaldehyde: Past, Present & Future	5
Many Roads Traveled	10
Sakura, Celebrating 130 Years of Excellence	12
Bone and Cartilage Changes in Osteoarthritis: a Proteoglycan Stain	14
All in a Day's Work: On the Front Lines Against Infectious Disease	16
Not All Eosins Are Created Equal	18

the cement would provide improved unit strength while the incorporated allograft bone would allow the patient's bone to grow into the construct, providing additional stability to this implanted biomaterial.



Fig. 2. Exakt Saw modifications that enabled uniform slab sections to be obtained.



Fig. 3. Bone/cement interdigitation is difficult to visualize in the unstained slab section.

For over a year, Dr. Marcus Hollis and staff engineer Bill Hogue worked on fabricating the machinery to produce the mold, and in 1995 Bill and staff engineer Charlene Flahiff got the machinery and the materials to all come together. The first crude prototypes were produced and there was an immediate need to see the interdigitation of the methacrylate cement with the allograft bone. The bone consists of cubes of cancellous bone that look very much like salad croutons, up to 10 mm on a given side. This material is often used in hip replacement surgery to make up for bone deficiencies in specific areas.

Previously our team used the Exakt system to study bone ingrowth into porous coatings applied to titanium femoral stem implants. The Exakt Macro Saw is a band saw equipped with a water-cooled, oil lubricated, diamond-edged blade that is used to cut thin, smooth wafers of bone and metal. We believed that if the saw could cut fine "slabs" of titanium, it should be able to cut cement and bone of comparable quality. Charles Stewart, a veteran of many years

working with undecalcified bone, was able to "freehand" cut four representative slabs from the prototype revealing a crosscut view of the penetration of the cement into the bone. Since the bone and the cement are a similar color, the need to distinctively color either the bone or the cement for better contrast became immediately apparent. Mr. Stewart's experience with photography and radiography led him to apply a 10% silver nitrate solution which he developed by leaving the silver-exposed slabs out in the sunlight. This process succeeded in darkening the bone and gave the investigators enough contrast to make the bone and its relationship to the bone cement more visible.

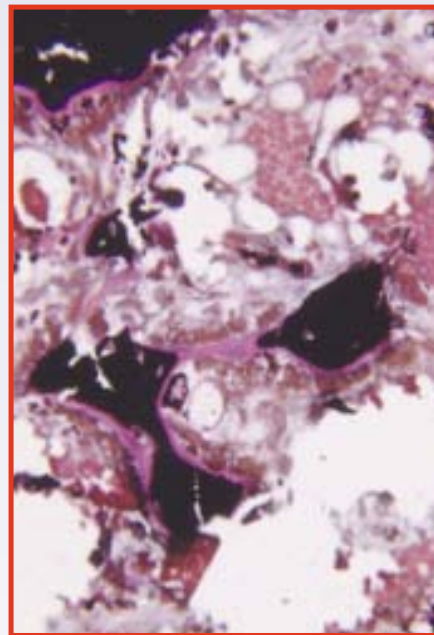


Fig. 4. von Kossa stain, Woodruff & Greenfield modification, performed on 2-micron section of glycol methacrylate-embedded undecalcified bone. The black areas are mineralized bone, the bright pink areas are osteoid, and the orange/red areas are associated connective tissue. 25x

This initial work led to sufficient data for two abstracts which were presented in 1997,^{1,2} and in 1999 an NIH Small Business Innovative Research (SBIR) Grant³ was awarded. Today, only two members of the 1995 tech group at UAMS remain and the investigational question no longer is "can this be done?" but rather "can this be done repetitively and consistently?" Under the

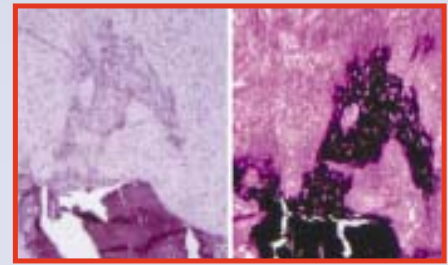


Fig. 5. Left: 2-micron section of GMA-embedded undecalcified healing bone fracture, Gill's III Hematoxylin. Dark purple = mature fractured cortical bone; lilac purple hook-like area = transchondral bone. Right: same field, von Kossa stain demonstrates mineralization of transchondral bone.

outline of the grant, the bone/cement relationship in the resulting slabs was to be evaluated via off-site image analysis. Therefore, the color contrast imparted to the bone had to be consistent from slab to slab as well as from cup to cup. We felt that freehand cutting would not yield reliably consistent slabs for the data to be statistically significant, and the silver nitrate contrast needed to be more tightly controlled.

Materials and Methods

The Exakt Macro Saw has several optional attachments which act as clamps or holders for materials to be cut. We deemed none of the holders on hand to be acceptable because of the potential for crushing the bone chips; another dilemma was not being able to adequately cut the portion of the cup which would have to be inside the holder. Years of cutting bone slabs with a standard band saw convinced us that the addition of a "rip fence" attachment to the Exakt saw would make slabs of consistent thickness attainable. Linda Durbin, president of Exakt Technologies, Inc., was consulted and after considerable discussion of options, we proposed attaching a length of 90° aluminum "L" bar to the standard support table approximately 1 cm from the blade to act as a fence, and a small aluminum block to act as a stop. We were willing to endure the water spray generated while holding the sample against the fence until Ms. Durbin suggested holding the cup in place with autoclave tape. This arrangement (Fig. 2) held the cup steady and took advantage of the gravity feed of the saw to get

the smoothest cuts attainable. The fact that the support table, fence, and backstop moved as a unit produced a minimum of roll typically associated with slabbing irregular objects on a band saw. The occasional roll that did occur was easily corrected by applying minimal additional pressure to the side of the cup. This process yielded from five to seven smooth, uniformly thick, cross-section slabs per cup (Fig. 3).

Finding a consistent “coloring” method for these slabs required some digging. A phone call to the now retired Charles Stewart revealed that the idea for his 10% silver nitrate/sunlight approach was based on a von Kossa procedure he had used in the early 1970s and was “somewhere in Lillie’s blue book” that he left behind in the lab. After reading several variations of the original von Kossa stain⁴ in this 1954 edition of Lillie,⁵ it was clear that the variability of several methods would not meet our needs.

Many years earlier with Dr. Leon Sokoloff at SUNY Stony Brook, I had used a modified von Kossa stain⁶ on 2-micron thick sections of glycol methacrylate (GMA)-embedded undecalcified iliac crest wedge biopsies that were then morphometrically evaluated for osteomalacia by measuring the osteoid associated with the mineralized bone in the biopsy (Fig. 4). More recently, I have used this stain for the demonstration of mineralized patterns in fracture healing (Fig. 5), and for a reactive model of bone in guinea pig femoral chondyle after biomechanical testing. In that work, the stain was applied to 1.5-2.5-micron sections of GMA-embedded undecalcified bone. It was our belief that since the von Kossa stain was useful for the morphometric analysis of GMA sections of bone, it might be suitable to study the mineralization of the hip cup prosthesis.

Our hope was that the silver nitrate would stain the mineral in the bone and not stain the bone cement, in

much the same way that embedded bone will stain, while the surrounding embedding medium does not.

The reagents and times used for each of the procedures were as stated⁶:

- 1.5% silver nitrate for 2 minutes in dark (dark=drawer under the bench top)
- 1.0% hydroquinone for 1 minute
- 2.0% sodium thiosulfate for 2 minutes



Fig. 6. Three-dimensional reassembly of stained composite cup sections.

There were some minor variations from the GMA staining protocol. The volume of reagents used was much greater. Whereas we generally stain our slides in a coplin jar, the slabs had to be stained in a staining dish. In order to cover the slabs, some of which exceeded 90 mm in length, approximately 125 ml of solution was required. The distilled water rinse times had to be extended from “three quick rinses” in between each step to soaking the slabs through multiple changes for an aggregate of approximately 1 minute in order to avoid carryover and to get the most mileage out of each reagent. The silver nitrate performed well for multiple slabs and was changed after each complete cup was stained. The hydroquinone had to be changed for each slab, as a precipitate would form. The sodium thiosulfate would stay clean for about four slabs. We decided that a counterstain was unnecessary because we were concerned with mineralization patterns and not cellular detail.

Results

Crisp demarcation of the trabecular bone (black) with a clean tan background (the original color of the

bone cement), was achieved. The results are consistent and reproducible for an evaluation of this type.

Discussion

While the procedure did provide the contrast required for evaluation, there were some inconsistencies in the tonal quality of the stained bone cubes throughout the study. We believe that these differences are due to a variation in mineral content of the donor bone which came from multiple sources; this is analogous to the way a pathologist might observe variations in diagnostic patient biopsies.

Conclusion

The authors wish to emphasize multiple take-home messages from our experience with this study.

Don't be afraid to experiment.

Someone, somewhere, was the first to try an approach that may now be routine for the rest of us. In our laboratory in the early 1980s, the GMA resins were largely used to prepare cartilage explants and cell pellets and later expanded to hematopoietic studies of bone marrow. I realized then that although orthopaedic research purists scoffed at the use of GMA processing for undecalcified bone because of its softness compared to other plastic embedding media, it was firm enough to provide sufficient support to the osteomalacia-compromised bone to yield adequate sections for interpretation in about half the time as preps in MMA and about half the cost, with equipment and expertise already on hand. For some projects the cost savings and reduced turnaround time may be more desirable than overall quality.

Do not hesitate to call on your equipment manufacturer.

The good reps realize the value of being helpful even if they don't sell you more stuff. Our initial call to Linda Durbin went from inquiring about a different design holder, then being assured that our modification would not void any intended use of the equipment mandates, to

thanking her profusely for the autoclave tape idea.

A digital camera, especially if you are doing off-site collaborations, can be invaluable. The immediate feedback of downloading a file and getting a response to “how’s this?” can significantly expedite projects, and in our situation has contributed much to small group efficiency.

Integrate your knowledge of different histology concepts. Our ability to see the big picture and willingness to think “outside the box” was key to our success in this investigation. We viewed the cancellous bone cubes, acrylic bone cement (described as a poly methyl methacrylate and barium sulfate mixture⁸), and the resulting undecalcified bone and bone cement composite as simply another type of embedded block to be cut and stained. We were able to customize the slab cuts to meet the statistical needs of the investigator, and after working out the physical logistics of the staining process we could then provide the color contrast based on what was basically a modification of a staining method dating back to 1901.

Perhaps most of all, **report your experiments and modifications** in publications like this. Even your most trivial ideas may be of value to others. If you don’t write them up and share them with the rest of us, you’ll never know what your ideas and creativity are really worth. While experience is always helpful, extreme expertise is not always a prerequisite. Noah’s Ark was built by an amateur; the Titanic was built by professionals. You do the math.

Acknowledgments

Many thanks to Dr. Leon Sokoloff for a wide range of concept introductions as head of SUNY Stony Brook’s Bone and Muscle Laboratory; Linda Durbin, president, Exakt Technologies, Inc. 7416 N. Broadway Extension Oklahoma City, OK 73116

This work was supported in part by Ortho Unique, Little Rock, Ark. and NIH ARAG46333.

References

1. Flahiff CM, Hogue WR, Nelson CL. Measurement of bone graft thickness and cement penetration in an acetabular allograft prosthesis. *Orthopaedic Research Society*; Feb., 1997; San Francisco, Calif.
2. Flahiff CM, Hogue W, Stems M, Nelson CL. A new acetabular prosthesis: An allograft/bone cement composite. *International Society for Technology in Arthroplasty*; Sept., 1997; San Diego, Calif.
3. Flahiff CM, Nelson CL, Hollis JM. *Acetabular Allograft Composite for Revision Hip Surgery*. NIH-SBIR grant; 1999.
4. von Kossa J. Ueber die im Organismus kuenstlich enzeugharen Verkalkungen. *Beitr Path Ant*. 1901: 163-202.
5. Lillie RD. *Histopathologic Technique and Practical Histochemistry*. New York, NY: McGraw-Hill; 1954: 264.
6. Woodruff J, Greenfield S. Advantage of glycol methacrylate embedding system for light microscopy. *J. Histochem*. 1979;2:164-167.
7. Kalscheur VL. Bone and cartilage changes in osteoarthritis: a proteoglycan stain. *National Society for Histotechnology*; 2000; Milwaukee, Wis.
8. Zimmer Bone Cement Instruction Sheet. Zimmer Corporation, Warsaw Ind.

Paraffin Cleansing Demystified

Gilles Lefebvre, Managing Editor

It is a fact that, during tissue processing, solution carryover from one station to the next is unavoidable. On the Tissue-Tek[®] VIP[™] tissue processors, this effect is minimized by blowing air through the lines after each pump-out sequence. However, even if all solutions are pumped out from the retort and the lines, tissue specimens will still be saturated with solution and the excess will be “given back” to the next solution pumped in. This carryover effect is even more pronounced when sponges are used.

Other than periodic reagent rotation, little can be done to minimize this effect for most solutions. The only exception is with paraffin. Clearing agents such as xylene will vaporize readily from molten paraffin and, in theory, can be extracted from paraffin. If you were to open the paraffin reservoir lid or the oven door while the instrument is operating, the

characteristic odor of the clearing agent in use will be strong. This is to be expected since the vapors are constantly created. If they are not removed, vapors will condense on the inside of the lid and drip back into the paraffin reservoirs.

Uncontaminated solid paraffin has a clear gray-white appearance and a smooth crystalline structure. Solid paraffin diluted with clearing reagent is a pure opaque white and presents a coarse crystalline structure. Molten paraffin contaminated with clearing reagent is oily and slick. Specimens infiltrated in a final paraffin station contaminated with clearing reagent will tear or explode when floated on the water bath.

Some manufacturers have recognized that paraffin can be degassed and thus, used for a longer period of time. A typical approach is to manually perform a special maintenance procedure where paraffin is pumped in the heated processing chamber and vacuum is applied to remove the released vapors. The procedure lasts about 60 minutes and must be performed separately for each paraffin station. The processing chamber must also be subjected to a cleaning cycle before processing tissue specimens. It should be noted that clearing reagent extraction should not be a substitute for paraffin rotation since degassing is never complete.

On the Tissue-Tek[®] VIP[™] tissue processors, a unique design feature is used to perform paraffin degassing automatically, while the instrument is processing tissue specimens. The use of an ejector located near the paraffin oven allows for the extraction of the clearing reagent vapors without having to perform an off-line maintenance procedure.

Using pressure and vacuum, the Tissue-Tek[®] VIP[™] tissue processor moves fluid in and out of the retort from solution containers located in the solution cabinet and the

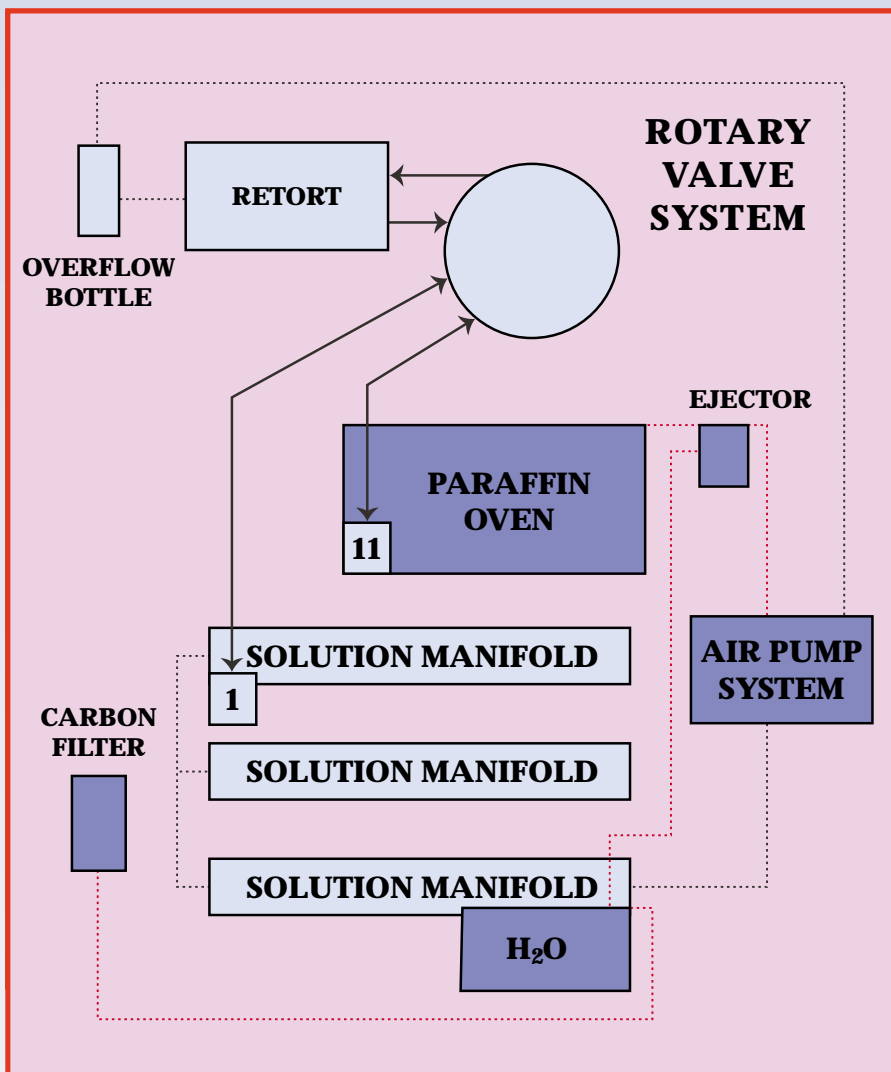
Formaldehyde: Past, Present & Future

Richard W. Dapson, PhD
Anatech Ltd.
Battle Creek, MI 49015

For more than a century, formaldehyde has been the most widely used fixative in all fields of histology except electron microscopy. In part, this has been because formalin, the aqueous solution of formaldehyde, has been the simplest, least expensive option. So-called "special" fixatives like Zenker's, Helly's, Bouin's, and many others contain expensive components, have short shelf lives, require limited exposure times for the specimens, or necessitate extra steps in the staining protocol to remove unwanted precipitate. Never mind that almost any of these produce striking morphological patterns or more vibrant colors. Cost and simplicity always win, whether today or a hundred years ago.

Keep in mind that before about 1980, the pace of clinical labs was far more relaxed than it is today. Specimens arriving in the morning were fixed all day and part of the night, while those arriving later in the day simply were held over until the following evening's run on the processor. Many labs followed recommendations in the leading textbooks for 24-48 hours minimum fixation.^{1,2} There was little rush for a diagnosis; when time was critical, frozen sections were the norm.

Formalin was king because it worked so well. In the times then allotted for fixation, beautiful preparations were routinely achieved on a consistent basis; in fact, they were expected by the "old masters" like Ham, Maximow, Bloom, and Fawcett, authors of standard textbooks of histology. Nuclear chromatin patterns depicted in their books were clearly defined and delicately speckled. Counterstain colors varied in shade



paraffin oven. The air and solution pathways are shown in the flow diagram, dashed lines representing air flow, solid arrows representing fluid flow. Colored components are the ones involved with the paraffin degassing cycle.

To prolong the useful life of the paraffin, the Tissue-Tek® VIP™ air pump applies pressure through the oven ejector (formerly called aspirator in older VIP models). As air is forced across the ejector, a vacuum is developed in the tube that connects to the oven. The clearing agent gases are therefore ejected out of the oven and

channeled through the water filter and to the activated carbon filter. Depending on the operating modes, paraffin cleansing is performed at different times during every automatic processing run. For example, degassing occurs at the end of every pump-in or every time a P/V cycle is completed. This ensures that clearing reagent vapors are removed periodically and thus, do not have the time to recondense and return into the paraffin. Since the process is automatic, there is no need to perform an off-line degassing procedure and the associated extra maintenance.

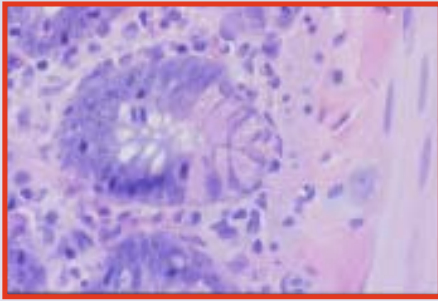


Fig. 1. Small intestine, NBF, 50x

according to tissue type (Fig. 1). Trichromes were really superfluous for many cases, but time was available and such special stains were ordered on nearly everything (or so it seemed).



Fig. 2. Formaldehyde. Carbon is gray, hydrogens are black, and oxygen is green.

Chemically speaking, formaldehyde's virtue is that it complexes with so many end groups on most tissue macromolecules. This is due to its reactivity. An aldehyde group (double-bonded oxygen) on a molecule with only one carbon atom (Fig. 2) is unstable (has high energy) and will attach to any other group that will lower that energy. Specifically, formaldehyde binds to sites containing a reactive hydrogen atom, including amides, amines, hydroxyls, peptides, sulfhydryls, and possibly carboxyls.²

Hydrogens can share their lone electron with other atoms. Carbon shares the electron equally with hydrogen, which is to say that the electron spends half its time around each atom. However, nitrogen, sulfur, or oxygen do not share that electron equally, with the result that hydrogen acquires a partial charge of about +0.3. This is a reactive hydrogen. It can be pulled off completely during covalent bonding, or can remain in place to engage in hydrogen bonding.

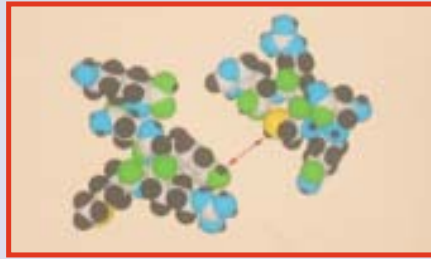


Fig. 3. Two polypeptides representing tissue macromolecules. Nitrogen is blue and sulfur is yellow. The double-headed arrow marks the points of attack by formaldehyde in subsequent modeling.

I have followed the course of fixation by formaldehyde through the use of molecular modeling software.³ For simplicity's sake here, we'll model the fixation and cross-linking of small polypeptides which will serve to represent adjacent tissue macromolecules (Fig. 3). While both have numerous potential reaction sites (active hydrogen atoms), we will use only the two marked with arrows. Each sphere indicates the size of the electron cloud around each atom. Note that hydrogen atoms attached to nitrogen, oxygen, and sulfur are smaller than those attached to carbon: these are active hydrogens. In subsequent figures, colors will be dimmed except for atoms germane to the discussion.




Fig. 4. Penetration of formaldehyde into the tissue. Only those atoms important to the rest of the discussion retain their original color coding; others are dimmed, although each polypeptide will be identifiable.

Step 1 in fixation is penetration (Fig. 4). Formaldehyde then attaches to an active site, a hydroxyl (-OH) group (Fig. 5). In a musical chairs sequence, formaldehyde's carbon replaces the active hydrogen which then joins formaldehyde's oxygen. This newly created hydroxyl group on formaldehyde's carbon is also reactive (note how small the hydrogen atom appears), and will combine with a second reactive hydrogen if one is conveniently available (Fig. 6).

We now have crosslinked molecules. In this final bridging reaction, the hydroxyl group of the former formaldehyde molecule and the reactive hydrogen on the sulfur atom split off to form a water molecule. What remains of the original fixative is a single carbon atom (with two hydrogens, only one of which is visible in the model) bridging the gap between the tissue molecules. This is called a methylene bridge (methyl denotes one carbon atom).

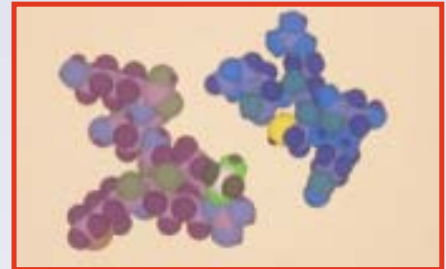


Fig. 5. Simple addition of formaldehyde onto a hydroxyl group in the first polypeptide. A hydrogen atom is transferred from the hydroxyl to formaldehyde's oxygen.




Fig. 6. Crosslinking. A water molecule is given off in this reaction (lower right). Note the spacing between the marked amino (blue and black) and carbonyl (green) groups.

The software lets me draw the structures any way I want, even if the conformation in three-dimensional space is not natural. The computer has been programmed with preferred lengths and angles for each type of bond, however, and can correct any shortcomings in my depictions. As initially drawn, some atoms may be in the way of each other. Neighboring atoms may have like charges that set up repelling forces or opposing charges that cause attractions. The computer considers all of these spatial and electrical needs, balancing them with optimal bond angles and lengths. Through a complex iterative process, it finds the most comfortable position for the population of atoms within the

molecule. In the end, calculations arrive at the best conformation, e.g., the one most likely to exist in nature.




Fig. 7. Molecular rearrangement to minimize energy. Compare the position of the amino and carbonyl here and in Fig. 6.

To appreciate this in our example, carefully compare the position of the blue polypeptide in Figs. 6 and 7. I have kept the violet polypeptide stationary. Figure 6 depicts the crosslinked polypeptides before optimizing the conformation. Below the methylene bridge are two primary amines on the violet polypeptide, each consisting of a nitrogen (blue) with two reactive hydrogens. The latter bear a +0.3 charge. Farther to the right is a carbonyl, an oxygen atom (green) that is double-bonded to the blue polypeptide. It carries a partial charge of -0.5. The distance between the farther nitrogen and the oxygen is 6.3. Charges and distances from atomic centers are determined by the software.

Now look at Fig. 7. Attractive forces between the negative carbonyl and positive amines have drawn the polypeptides together, closing the gap to 2.8. This produces several subtle, but important changes. First, the partial charges at the aforementioned sites have been essentially neutralized. This alters the charge characteristics of the molecule. Second, two hydrogen bonds have formed. Although these are weak, they do supplement the methylene crossbridge and thus, strengthen the overall connection joining the formerly independent polypeptides. The molecule has become more rigid. Third, shrinkage of the overall tissue occurs as parts of molecules move together. Finally, the former polypeptides have changed shape,

and not simply by joining together. Portions are twisted relative to the original conformations. Because microbial and endogenous enzymes depend upon key-in-lock fits to their substrates, decay and autolysis are inhibited. In short, the specimen has been denatured, or fixed.

In reality, fixed molecules are joined by many crossbridges and even greater numbers of other types of bonds (ionic, hydrogen, and van der Waal's attractions) than I have shown in this simple polypeptide model. This produces denaturation on a grand scale. Keep in mind, however, that crosslinking is a slow process, and there are many other ways to effect denaturation. Formalin-induced denaturation is considered good for morphology, but bad for histochemistry involving enzymes and immunologic reagents. Heat and solvents like alcohol are also effective denaturants, but they change molecular shape differently, which usually results in poor morphological patterns.

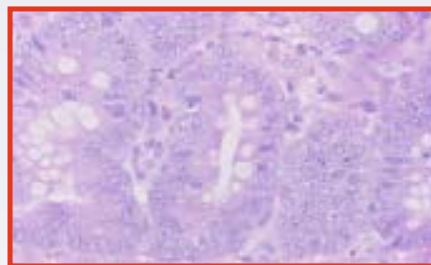


Fig. 8. Bubbling artifact in both nuclei and cytoplasm due to mildly inadequate fixation in NBF. Colon. 50x

Tissue molecules fixed in formalin for 24-48 hours acquire so many crosslinks and other connections that they are unable to be altered by other chemical or physical agents normally encountered in processing and staining. In contrast, weakly fixed specimens can be re-denatured by alcohol and heat, which is why so many tissues today show striking artifacts. Nuclear and cytoplasmic bubbling (Fig. 8) occurs when chromatin is moderately fixed (7-24 hours) in formalin, then further denatured during the rest of processing. Less well-fixed nuclei (0-7 hours in formalin) suffer greater alteration from alcohol and heat:

chromatin patterns are lost altogether, with some nuclei taking on odd colors (Fig. 9). Because the daily run of specimens in a lab may include those with little, if any, fixation as well as tissues with a day or more of formalin exposure, variation in the appearance of the slides is rampant through no fault of the stains or the technicians.

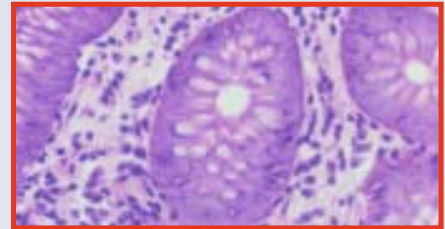


Fig. 9. More severe damage from inadequate fixation in formalin. Intestinal biopsy. 50x

Today there is an intense push for faster turnaround of specimens. Laboratories have sacrificed fixation time to gain this speed in utter disregard for the chemistry of formalin fixation. Unfortunately, the reality is that few histopathology facilities have the luxury of 24-48 hour fixation. Clearly, neutral buffered formalin is no longer suitable for our needs from that standpoint alone, never mind safety issues and immunohistochemistry.

Formalin is one of the worst fixatives for immunohistochemistry. True, most immunostaining is performed on formalin-fixed tissue, but look at the lengths to which we go to get results. The literature on reclaiming antigenicity is overwhelming, with enzymes and heat vying for preferred status. Even the method of heating and the attendant retrieval solutions are highly diverse. No one method is best for everything. Different antibodies require different techniques, and different labs often have to use different methods for the same antibody because of local variations in fixation. I have always wondered why we spend so much time trying to save a ruined specimen when it is so easy to get excellent structural preservation and retain full immunoreactivity. Said another way, why compromise a specimen with formalin fixation just

because we have procedures that might retrieve the antigens? We use these techniques to avoid false negative reactions but sometimes we create false positives instead.⁴

When OSHA first initiated the Formaldehyde Standard in the United States, all attention seemed to be riveted on the carcinogenicity of this chemical. It is a human carcinogen, let no one doubt that. The Preamble to the Standard details the evidence. However, that is not the health risk that histotechnologists need to be most worried about. Formaldehyde is a potent sensitizer, whether through inhalation exposure or skin contact. Did you know that 79% of histotechs have dermatological and respiratory symptoms attributable to formaldehyde exposure?⁵ They get colds more frequently, and that last longer, than non-exposed individuals. Their incidence of asthma is higher. They suffer from dermatitis. Sensitization is an immunological condition that lasts for life. In a world where formaldehyde vapors come out of carpets, wall coverings, draperies, furniture, and many building materials, the sensitized individual is going to have a rough time.

Are there satisfactory substitutes for formalin? Definitely yes! Any of the zinc formalin solutions eliminate the technical problems, although the safety concerns are still present. Immunoreactivity is fully preserved even after months of storage in zinc formalin. Homemade and commercial products abound, with unbuffered, buffered, and alcoholic buffered versions available. Zinc formalin in some form or another has been used widely since the early 1980s, and there is an impressive body of literature on the subject.⁶

Finding a completely different alternative to formaldehyde has been more challenging. Ideally, the new fixative should create morphological patterns similar to those seen with excellent formalin fixation, but immunoreactivity should be retained. Human and environmental safety factors must be favorable. If

you scan the list of fixative components in any textbook of histotechnology or histochemistry you will find none that meet these criteria. Clearly a major breakthrough was needed to bring histological fixation into the twenty-first century. In actuality, the breakthrough was made several times with a variety of unrelated chemicals, all but one contained in proprietary mixtures. Some of these do not create fixation patterns quite like formalin because they are not aldehyde and may not be fixatives in the true sense, as much as they are effective transport solutions. Since the identity of their ingredients remains secret, we cannot divine their modes of action nor really understand their limitations.




Fig. 10. Glyoxal.

The chemical that has surfaced as the one most likely to replace formaldehyde is glyoxal, a very close relative containing 2 carbon atoms and 2 aldehyde groups (Fig. 10). It adds onto the same reactive tissue groups but with greater speed. Crosslinking is either prevented despite the second aldehyde, or the 2-carbon crossbridge is too long to block immunoreactivity. Curiously, glyoxal essentially has no vapor pressure, which is why it does not evaporate or give off fumes. Inhalation risk is therefore reduced to zero, certainly below any known conditions of use in histology, including microwave fixation. Drain disposal is almost always permitted by local authorities because of glyoxal's low level of ecotoxicity. A number of vendors offer both ready-to-use solutions and concentrates. After being on the market for 8 years, glyoxal fixatives have created an impressive record.

Deservedly, they have become the most widespread alternatives to formalin in the United States.

Short fixation times with glyoxal do not produce the artifacts that are so common with formalin. Biopsies can be fixed quite adequately in 45-60 minutes⁷ and superbly in 2 hours. Surgicals take 4-6 hours after grossing.⁸ Alcoholic versions, available from some vendors, work even faster.

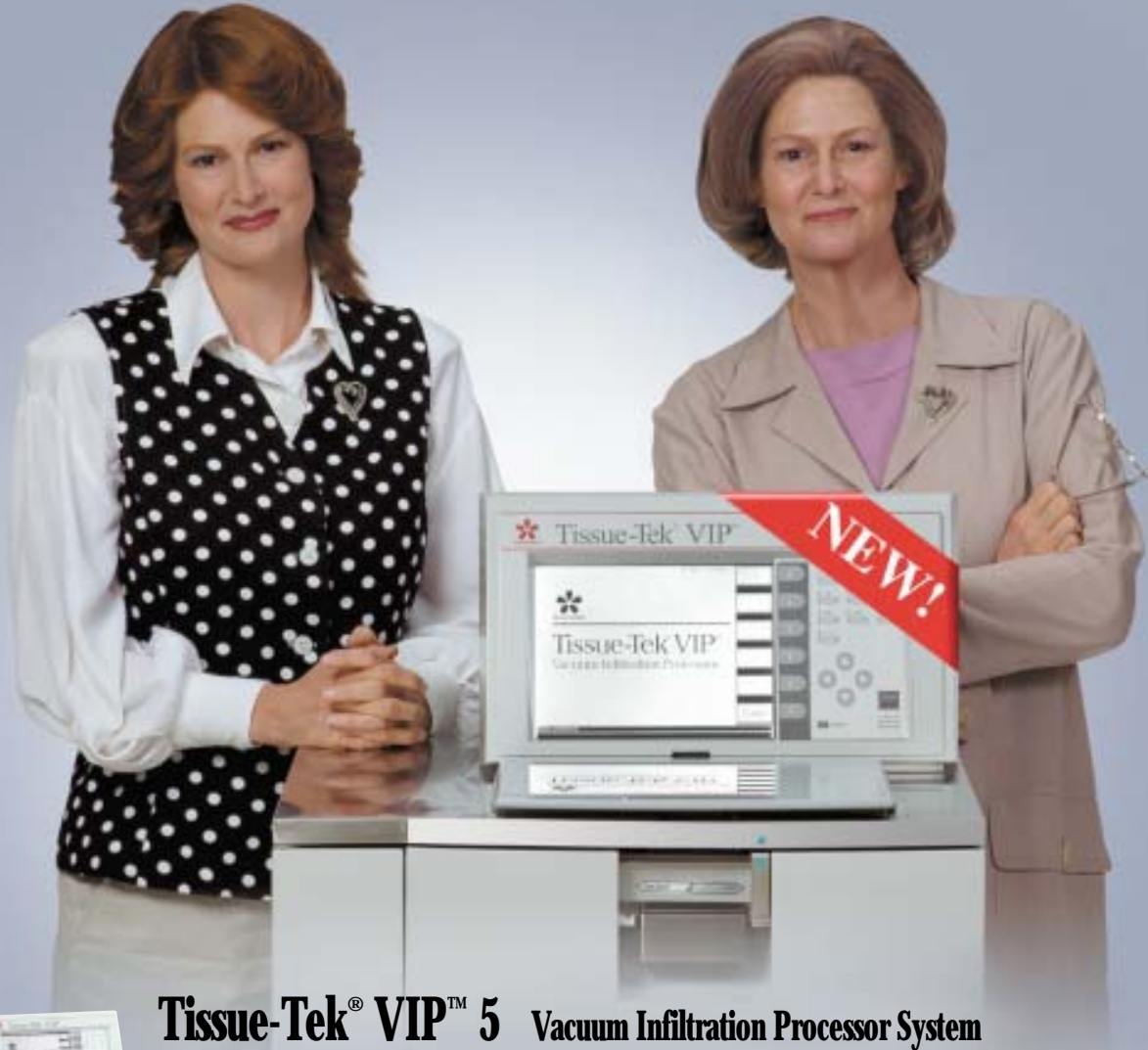For the ultimate in speed, consider microwave fixation in an appropriately vented and temperature-controlled appliance, using either the conventional glyoxal fixatives or those created especially for microwave applications. Initial fixation at the point of specimen origin can be in any common fixative, including one of the glyoxal solutions. Non-glyoxal fixatives should be rinsed out by soaking grossed specimens for 20-30 minutes in the microwave fixative at room temperature. Microwave in the glyoxal solution for 4-16 minutes and you are ready to process.⁹ Talk about reducing turnaround time!

Formaldehyde has had a glorious past but a troubled present. It now faces a rather dim future. Change comes slowly, especially in our field, but it is time to move on. This is just one more example of how dynamic histotechnology is, and why it is exciting to be a part of it.

References

1. Lillie RD. *Histopathologic Technique and Practical Histochemistry*. 3rd ed. New York, NY: McGraw-Hill; 1965:33,36.
2. Pearse AGE. *Histochemistry, Theoretical and Applied*. 3rd ed. Boston, Mass: Little, Brown; 1968:1,70,73.
3. CS ChemOffice Ultra. CambridgeSoft Corp. Cambridge, Mass.
4. Margiotta M. Atypical cytokeratin staining of sentinel node biopsies for breast cancer due to microwave pretreatment. *Histo-Logic*. 1993;1(2):22-23.
5. OSHA. Occupational exposure to formaldehyde. *Federal Register*. 52(233):46168-46312.
6. Dapson RW. Fixation for the 1990s: a review of needs and accomplishments. *Biotechnic & Histochem*. 1993;68(2):75-82.
7. Strine E. Improving biopsies diagnostic cycle-time while preserving optimal cellular morphology. Shandon Lipshaw Lab Leader. 1996;11(2):8-9.
8. Anatech Ltd. A solution to the irritating problems of formaldehyde. *The Innovator*. 1999;3(1):1-6.
9. Anatech Ltd. From patient to embedding center in two hours or less. *The Innovator*. 1998;2(2):1-4.

**PEACE OF MIND.
A VIP THEN. A VIP NOW.**



Tissue-Tek® VIP™ 5 Vacuum Infiltration Processor System



With the **Tissue-Tek® VIP™ 5**, Sakura brings today's histology laboratories the fifth generation of an instrument recognized the world over as *the laboratory standard* for its unmatched efficiency and reliability.

The **VIP™ 5** both streamlines and speeds the processing of tissue samples, offering twenty different processing programs, external reagent drain and fill, automatic reagent transfer, and continuous mixing. Taking the lead in innovation, quality, and reliability is nothing new for you—or the **VIP™**.

For more information, contact your Sakura Area Manager today. Call 1-800-725-8723. Don't delay.

*Proven
Reliability*



Sakura Finetek U.S.A., Inc.
1750 West 214th Street
Torrance, CA 90501 U.S.A.
Phone: (800) 725-8723

Many Roads Traveled

**Diane Sterchi, MS,
HTL(ASCP)HT, EMT(MSA)**

Each year at the National Society for Histotechnology (NSH) Symposium/Convention one needs only to peruse the job postings to appreciate how many laboratories are trying to fill positions. The American Society of Clinical Pathologists (ASCP) recently posted vacancy rate data for various medical lab positions at its web site (file:///C:/WINDOWS/TEMP/survey.html). This illustrates what many of us are already struggling with. The national vacancy rate for histotechnicians is 16.1%, up from 12.9% in 1998. Vacant histotechnologist positions have doubled in the same period, from 10.3% to the current level of 22.3%. Histology supervisor positions have doubled (20% vacant) since 1996.

Why is it so hard to find individuals to fill these positions? After all, we love what we do and have the best careers, so why is it that others are not flocking into such a challenging field? Is it possible that we inadvertently discourage the enthusiasm of those investigating career paths due to our own limited knowledge of career options for histotechs?

After conducting several recruitments of my own, many culminating in the hiring of individuals fresh out of school, I realized that some individuals looking to break into the field are fascinated with what we do but want to know of work settings outside of the hospital or university lab—an environment which may not appeal to everyone. It would well serve those of us in the field to become more informed about the opportunities available in the domain of histotechnology. One way to do this is to have histotechnicians write about their histology skills and techniques, or the uniqueness of their laboratories, in order that we may open up the world of histotechnology to non-histotechnicians. There is an amazing world in histo-

technology and we need to get this information out to prospective histotechs.

In this vein I offer you a glimpse of the roads I have traveled during the evolution of my career in histology in the hope that others will be encouraged to write about theirs.

The author's career began as many do, in a hospital histology laboratory setting. I began working part time for the first six months during my initial training period and then full time, eventually becoming supervisor within the first year. I remained there for the next five years. It was an exciting new career since the hospital and pathologists provided and encouraged many learning opportunities inside and outside of the facility. Like many hospitals, our tissues were processed overnight, cut and stained by mid-morning; the pathologist read them by afternoon, followed by grossing, and then special stains. This was a 200-bed facility with six surgical suites, which would yield about two thousand cases a year. Often there would be requests for special stains, or for assistance with an autopsy, but all in all it was a fairly routine histology laboratory. During the last two years at the hospital, immunohistochemical techniques (that were new to everyone at that time) became a weekly request on our special technique list. That road provided the learning and the basics of all histotechniques and it is where my love of histotechnology really began.

The second road taken was a part-time position in a veterinary histopathobiology laboratory located at a large university. The processing of animal tissue became the next new learning challenge. Although the processes and time lines were similar, the procedures we used were modified for animal tissue. The supervisor in this laboratory was patient and trained us all very well. She expected the highest quality of slides from herself and her coworkers, but she also made sure that she did a good

job in training to assure such high quality. Along with the diagnostic samples there were research samples to process, and some of them required glycolmethacrylate embedding. Learning to embed, microtome, and stain glycolmethacrylate-embedded tissues was a new endeavor for me.

A few months later, the laboratory started to invest time in learning immunohistochemistry (IHC). This technique was still very new in human diagnosis, and antibodies that would react in animals were not readily available. With a lot of trial and error, along with training (more learning opportunities), the IHC with frozen and some paraffin-embedded sections started being used during my part-time employment there. Since leaving this lab, they have become so successful in developing IHC methods that they have made available a never-ending list of stains to offer to pathologists and researchers. It is not clear as to whether or not the lab became successful because I departed, but it was exciting to be there in the beginning.

Around this same time, a part-time position for a histology research specialist opened in another department. Here I had the opportunity to explore museum specimen preparation, some of which included cataloging and organizing historical and teaching data (Kodachromes, slides, blocks, and case studies), electron microscopy (TEM & SEM), undecalcified bone preparation, preparing class slides for the veterinary student's histology class, plus routine animal histology. Eventually this led to a full-time, supervisory position that included specialization in undecalcified bone processes and immunohistochemistry, assisting with teaching histology, and teaching a graduate course in histotechniques.

One of the projects that I found interesting was studying the different methods of treating fetlocks in horses. This project required methylnmethacrylate and

paraffin embedding of tissues that measured anywhere in the range of 3-5 inches wide and 4-8 inches long. It also involved using x-rays, along with Magnetic Resonance Imaging (MRI). The pathologist read the paraffin sections, and the methylmethacrylate sections were scanned and the images were loaded into a computer. These images were then compared to the radiographs that were also scanned and loaded into the computer. A 3-dimensional layered image was the end result of all the serial sections, x-rays, and MRI images. Here researchers could see the effects of the treatment type on living and fixed tissues.

Another project used serial sections of porcine nasal turbinate to study the damage that is done to the respiratory and olfactory epithelium from upper respiratory infections. Respiratory infections can cause premature death in pigs and affect an entire herd (known as drift), thus causing a tremendous loss of income to the farmer. Whole snouts of more than 100 animals were processed, half into paraffin and the other half into methylmethacrylate. The reason for embedding half into methylmethacrylate was to observe the different epithelial cell layers without the damaging effects of decalcification. All paraffin blocks were serially sectioned by using tape to hold them together, and the methylmethacrylate blocks were cut into slabs with diamond blades on water-cooled saws, ground to the desired thickness, and polished with an ultramiller. This project prompted two other projects that led to technique publications, with more to come in the future.

The nicest thing about moving into research was that the turnaround time was determined not by tight deadlines, but rather the time needed to achieve the perfect slide. I had the dream job and it just kept getting better.

As luck would have it, after nine years of learning and growing stronger in histotechnology, a

new opportunity presented itself. This led me to the world of biotechnology where I became involved in the design and implementation of a histology laboratory filled with water-cooled saws, grinders, polishers, microtomes, tissue processors, cytopins, PCR thermal cyclers, a confocal microscope, inverted scopes, and most of all, imagination. Here we developed methods to track cells in tissues by performing special immunohistochemistry and in situ hybridization on cell cultures, pellets, and plates, along with the specialized histology techniques of undecalcified bone and implant preparation.

One of the most challenging projects that came into the laboratory was to develop a method in which labeled primary cells that were transplanted into a living donor, could be used to detect the primary and secondary cell migration in the tissues one year later. This study was one of many studies associated with breast cancer research. Marrow from a non-human donor was required; cells were grown to increase the total number of cells, and labeled with a fluorescent label. Radiation was used to remove the existing cells in the donor before infusing treated cells back into the donor. At necropsy (animal autopsy) one year later, we removed all of the tissue and started our search for labeled cells. The cells no longer fluoresced, but we did find an antibody that would attach to the labeled cells and we were successful in tracing where the cells traveled in the living body.

This was one of the many exciting projects where I, as a histotechnologist, had an opportunity to learn cell culturing, and how to attach a label to cells, in addition to planning, testing, and participating in the development of techniques that were unique to the company, while still getting paid for having fun.

Today I am back to the quick turnaround, high volume, and routine

processing of animal tissues in a toxicology laboratory. When time permits, non-routine processes are being introduced into the laboratory. Here most techniques are modified or redesigned to cut down on turnaround time, and these modifications are developed by the histotechnicians working within the laboratory, not just supervisors or lead technicians. This way everyone has an opportunity to specialize, grow technically, and train others. There are two specialized areas that depart from the routine—undecalcified bone sectioning and immunohistochemistry—where the technicians rotate assignments and have the opportunity to learn new techniques.

Opportunities in the field of histotechnology are virtually limitless, but one must realize that these opportunities come with a price. They are not handed to us with a note of gratitude. Sometimes being in the right place at the right time helps, but not always, and one should not depend on that happening. The only way that anyone can be assured of an opportunity is to want it badly enough to make it happen. It must be a desire that is strong enough to challenge you to work hard and learn as much as you can. You have to have a strong foundation in the basics but be willing to reach beyond old teachings in order to make new things happen. Earning a reputation of always doing the job well *will* get you where you want to go in the field of histotechnology.

After having the opportunity to travel many roads myself and looking forward to those ahead, I find it amazing that others may not find histotechnology as interesting. So it is up to each of us to reveal the many roads of histotechnology to others with pride and enthusiasm in the hope that we have inspired and recruited the next generation of histotechnologists prepared to meet the challenges of the future.



130

CELEBRATING 130 YEARS OF EXCELLENCE

Founded in 1871, Sakura traces its historic roots to even earlier times

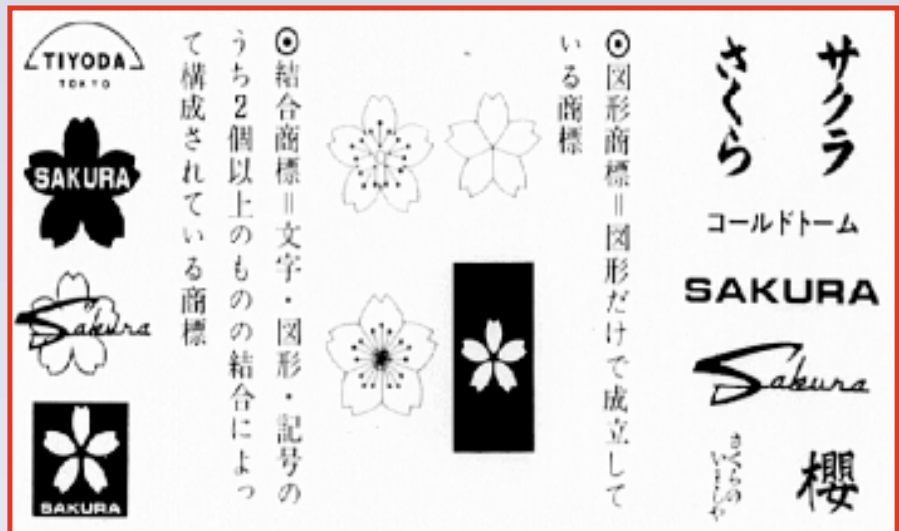

Medical Equipment Illustrated Catalog issued in 1878. Sakura produced this comprehensive medical equipment catalog in Japan.

Sakura Finetechnical Co. Ltd., was formally established in April 1871. But as with every great story, there is more to it than that. Early records show that the firm began as a small pharmacy, selling medicine for stomach problems, as early as 1825. As success followed, the original company was founded as a pharmaceutical manufacturing and sales establishment known as Iwashiya—which began its manufacturing business in 1830.



Bridging the past and the future: the Tokyo office from 1860 to 1923, and the new Sakura Laboratory Business Headquarters in Torrance, CA.



Sakura logo was implemented in 1903.

Putting that into the perspective of US history, in 1830 Andrew Jackson, the seventh president of the United States, was in his second of eight years in office; the first passenger railroad in the United States began service between Baltimore and Elliott's Mills, Md.;

the first plans for the city of Chicago were laid out; and the non-Indian population of California was 4,256. From those earlier, humble beginnings success followed success—and continues to this day. Take a moment to browse the documents that detail the historical record presented here. It is interesting to note that the newly formed medical equipment division of Iwashiya first registered its trademark of "Sakura," the now-familiar five-petaled cherry blossom, in 1887. Sakura issued the first comprehensive medical equipment catalog in 1878, the front cover of which appears on this page.



130th Anniversary Event.

We invite you to review the beginning of the proud history of today's Sakura Finetek USA. It is a remarkable progression from a far-distant past into the technical legacy it expands on every day.

Happy 130th. And many more.



**LOOKING GOOD.
WORKING SMART. YEAR AFTER YEAR.**



Tissue-Tek® TEC™ 5 Tissue Embedding Console System



Through the years, each generation of the **Tissue-Tek® TEC™** has maintained an outstanding record of innovation, quality, and reliability. The **Tissue-Tek® TEC™ 5** is sure to be no exception. Sakura has designed a fifth-generation instrument that optimizes operator control and efficiency—and improves workflow—throughout the tissue embedding process.

From a 4-liter paraffin chamber to ample hot and cold surfaces to menu-driven programming, the **TEC™ 5**, like you, is looking and working better than ever.

For more information, contact your Sakura Area Manager today. Call 1-800-725-8723. Don't delay.

*Proven
Reliability*



Sakura Finetek U.S.A., Inc.
1750 West 214th Street
Torrance, CA 90501 U.S.A.
Phone: (800) 725-8723

Bone and Cartilage Changes in Osteoarthritis: a Proteoglycan Stain

V.L. Kalscheur, HT (ASCP)
 Comparative Orthopaedic
 Research Laboratory
 University of Wisconsin
 School of Veterinary Medicine
 Madison, WI 53706
 (608) 262-8534
 e-mail
 kalschev@svm.vetmed.wisc.edu

Introduction

The relationship between bone and cartilage is well documented in osteoarthritis studies. Radiographic examination identifies degenerative changes (Figs. 1, 2). Histologically, the *Safranin O Stain* demonstrates articular cartilage proteoglycan and is helpful in determining the degree and location of articular loss and subchondral bone activity. Osteoarthritis (OA) is the age related, gradual wearing down of the joint surface, causing pain and stiffness.

General Information

The joint surface is made up of articular cartilage (AC), found in joints such as the knee, hip, and shoulder. The role of AC is to act as a “bearing” surface for joint motion, and as a stress buffer to the underlying bony structures. The structural organization of AC consists of chondrocytes in a matrix composed of:

- 10% Collagen fibers (protein, lipid)
- 80% Water/inorganic salts
- 10% Proteoglycan

AC is avascular. Additionally, the chondrocytes do not have the ability for mitotic activity. Once damaged, the *mechanical breakdown* of cartilage triggers the degenerative process known as osteoarthritis, or degenerative joint disease. The underlying subchondral, then trabecular, or cancellous bone, also stiffens and starts to degenerate over time. Normal articular cartilage is divided into zones (Fig. 3).

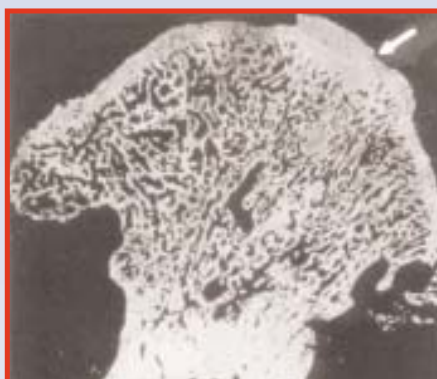

Fig. 1. Osteoarthritis: Canine hip joint. Irregular articular surface with underlying thickened trabeculae (arrow) indicates arthritic bone matrix that will eventually soften and collapse. 4x

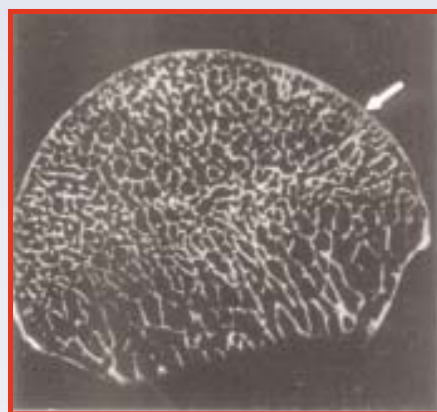


Fig. 2. Normal: Canine femoral head. Smooth articular surface with clearly defined trabeculae (arrow). 4x

The *Safranin O* procedure selectively stains proteoglycan, a major component of articular cartilage matrix, which is decreased in OA. Proteoglycan consists of core protein, chondroitin sulfate, keratan sulfate, glycosaminoglycans, link proteins, and hyaluronic acid. Proteoglycans reside in the fibrous network of collagen and are responsible for the compressive strength of cartilage. Water binds with proteoglycans and collagen to make cartilage tough and resilient. Proteoglycan can break down or degrade very rapidly.

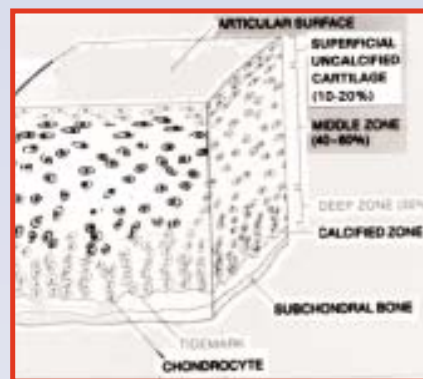


Fig. 3. Diagram of mature articular cartilage “zones.” Reprinted with permission from Mow, Proctor, Kelly (reference 7).

Materials and Methods

Safranin O is an orange, meta-chromatic dye that readily shows the architecture along the articulating surface to the tidemark. It stains the cartilaginous areas an orange/red color. With proteoglycan loss, the stain is less intense. *Fast Green (FCF)* is the counterstain for subchondral, mineralized bone. In our protocol, *Mayer's Hematoxylin* is used for nuclear staining (Figs. 4, 5).



Fig. 4. Osteoarthritis: Pale red, irregular staining pattern along articular surface clearly indicates cartilage loss and destruction from mechanical wear and tear, and contrasts with the thickening subchondral bone (green). 20x

Tissue samples are fixed in 10% neutral buffered formalin, sliced into 2-mm sections, and decalcified in citrate buffered formic acid or EDTA until all calcium salts are removed. Samples are processed, embedded in paraffin, sectioned at 6 microns, and stained.

Superficial	“Gliding” surface, densely packed cells, minimal proteoglycan, high water content	(10%-20%)
Middle	Fibers separating, cells less organized, proteoglycan/protein production area	(40%-60%)
Deep	Large, loose bundles of cells in columns, high concentration of proteoglycan	(30%)
Tidemark	Separates cartilage from bone	
Calcified	Cartilage “interlock” with subchondral bone	

The *Safranin O* method gives excellent results in studying the relationship between bone and cartilage in OA (Table I). Intensity of the Safranin stain uptake is determined by loss of proteoglycan, and procedure times vary according to species. *Safranin O* is ideal for the histologic-histochemical grading (Mankin) of osteoarthritic lesions of AC, as well as cartilage structure, cell distribution, and proliferation, stain intensity (Table II). The Mankin Grade is a subjective scoring system frequently referenced in OA studies.

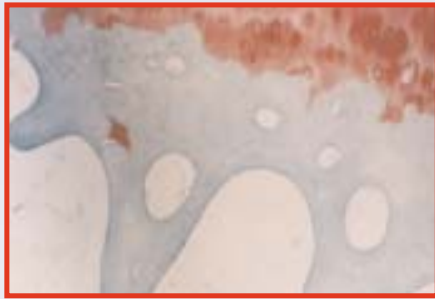


Fig. 5. Normal: Cartilaginous area stains a deep, even red color, with consistent cell distribution. The subchondral bone architecture is normal (green). 20x

Summary

The *Safranin O* method, combined with radiography, clearly indicates decrease of proteoglycan due to the disease process. Osteoarthritis is primarily a degenerative disease of the cartilage with secondary bone changes. Noticing the changes that occur in AC and subchondral bone contributes to the understanding of this inevitable condition. For our purposes, the described staining technique gives excellent results in osteoarthritis studies.

References

1. Buckwalter JA, Mankin HJ. Articular Cartilage (parts I, II). *J Bone Joint Surg.* 1997;79A:600-632.
2. Bullough P. *Atlas of Orthopaedic Pathology.* New York, NY:Gower Medical Publishing; 1992:9.4-10.20.
3. Conn HJ, Lillie RD. *Biological Stains* Baltimore, Md: Waverly Press, Inc; 1977:254,387.
4. Hulth A. Does osteoarthritis depend on growth of the mineralized layer of cartilage? *Clinical Orthop.* 1993;287:19-23.
5. Mankin HJ, Dorfman H, Lippiello L, Zarins A. Biochemical and metabolic abnormalities in articular cartilage from osteoarthritic human hips. *J Bone Joint Surg.* 1971; 53A:523-537.
6. Prophet EB. Laboratory methods in histochemistry. *American Registry of Pathology.* Washington D.C: 1992:53-55,167.
7. Mow, Proctor, Kelly. *Basic Biomechanics of the Musculoskeletal System.* Lea & Febiger. 1989:Section I.

TABLE I
SAFRANIN O METHOD*

SOLUTIONS
MAYER'S HEMATOXYLIN OR
IRON HEMATOXYLIN
(WEIGERT'S) WORKING
SOLUTION

0.02% FAST GREEN (FCF)
SOLUTION

Fast green,
FCF, C.I. 420530.2 g
Distilled water1000.0 ml

1% ACETIC ACID SOLUTION
Acetic acid, glacial.....1.0 ml
Distilled water99.0 ml

0.1% SAFRANIN O SOLUTION
Safranin O, C.I. 502400.1 g
Distilled water100.0 ml

Procedure

1. Deparaffinize and hydrate to water.
2. Stain with Mayer's for 15 minutes or Weigert's iron hematoxylin working solution for 7 minutes.
3. Wash in running tap water for 10 minutes.
4. Stain with fast green (FCF) solution for 3-10 minutes.
5. Rinse quickly with 1% acetic acid solution for no more than 10 to 15 seconds.
6. Stain in 0.1% safranin O solution for 5-15 minutes.
7. Dehydrate and clear with 95% ethyl alcohol, absolute ethyl alcohol, and xylene, using 2 changes each, 2 minutes each.
8. Mount using resinous medium.

Results

Nucleiblack
Subchondral mineralized boneshades of green
Cartilaginous areasorange to red

References

- *Modified from: Laboratory Methods in Histochemistry, AFIP, Washington, D.C.,1992:167.**
1. Lillie RD, Fulmer HM. *Histopathologic Technic and Practical Histochemistry,* 4th ed. New York, NY: McGraw-Hill; 1976:657.
 2. Conn HJ, Lillie RD. *Biological Stains,* 9th ed. Baltimore, Md: Waverly Press; 1977:387.

TABLE II

New and Improved Histological-Histochemical Grading System for Articular Cartilage

Grade Structure

- | | |
|---|--|
| 0 | a. Normal |
| 1 | b. Surface irregularities |
| 2 | c. Pannus and surface irregularities |
| 3 | d. Clefts to transitional zone and superficial disorganization; loss of boundary between tangential and transitional zones |
| 4 | e. Clefts to radiate zone +/- disorganization of radiate zone; +/- loss of superficial layer(s) |
| 5 | f. Progression of cartilage loss into radiate zone; +/- clefts to radiate zone and/or the calcified zone |
| 6 | g. Absent down to the tidemark (eburnation) |

Cells

- | | |
|---|-----------------------------|
| 0 | a. Normal |
| 1 | b. Diffuse hypercellularity |
| 2 | c. Cloning |
| 3 | d. Hypocellularity |

Staining

- | | |
|---|--|
| 0 | a. Normal |
| 1 | b. Slight reduction in staining, +/- staining reduced in radiate layer |
| 2 | c. Moderate reduction +/- reduction in interterritorial matrix |
| 3 | d. Severe reduction +/- only present in pericellular matrix |
| 4 | e. Staining absent +/- occasional rim of pericellular matrix staining |

Tidemark Integrity

- | | |
|---|-----------------------------|
| 0 | a. Intact |
| 1 | b. Crossed by blood vessels |



On the Front Lines Against Infectious Disease

**Tim Morken, BA, EMT(MSA),
HTL(ASCP)**
**Centers for Disease Control
and Prevention**
Atlanta, GA

Ebola. Influenza. Rift Valley Fever. Dengue hemorrhagic fever. Hantavirus. Anthrax. These infectious diseases strike fear into the hearts of all medical personnel and conjure visions of spacesuited scientists working to control them. They are also the province of the Infectious Disease Pathology Activity (IDPA), at the Centers for Disease Control and Prevention, where all tissue samples from infectious disease outbreaks are sent for diagnosis, and where research is conducted on the pathogenesis and prevention of infectious diseases.

The Centers for Disease Control and Prevention (CDC) is a US federal agency based in Atlanta, Georgia. The CDC is part of the US Public Health Service which, in turn, is part of the Health and Human Services Department. The IDPA is a branch of one of the nine "Centers" of the CDC: the National Center for Infectious Disease (NCID).

The mission of NCID is to prevent illness, disability, and death caused by infectious diseases in the United States and around the world. To accomplish this goal, NCID staff work in partnership with local and state public health officials, other federal agencies, medical and public health professional associations, infectious disease experts from academic and clinical practice, and

international and public service organizations. NCID accomplishes its mission by conducting surveillance, epidemic investigations, epidemiologic and laboratory research, training, and public education programs to develop, evaluate, and promote prevention and control strategies for infectious diseases.

Infectious diseases are the leading cause of death worldwide, and deaths from infectious diseases in the United States have been increasing. Infectious diseases ranked third among the leading causes of death in 1992 in the United States.

organizations. The IDPA also performs diagnostic service for individual cases of suspected infectious disease.

The IDPA staff consists of three pathologists, five histotechnologists, three electron microscopists, one molecular biologist, two research microbiologists, and several support staff. Several visiting research fellows are also in residence at any given time. The IDPA collaborates with many other branches of the NCID in any tissue-based research, so the scope and opportunities are very broad.

RIFT VALLEY FEVER
Hantavirus Anthrax
EBOLA
DENGUE HEMORRHAGIC FEVER

The IDPA participates in the NCID mission by serving as a scientific and technical resource to other NCID branches (such as Influenza, HIV, Special Pathogens, etc.). This is accomplished by the following four strategies: 1) providing expertise in molecular pathology, histopathology, and ultrastructural analysis for detecting infectious disease agents, and studying the interactions between microbial agents and host cells. Bacterial, viral, and parasitic microbes are all studied in IDPA; 2) developing, improving, evaluating, and applying special ultrastructural, immunohistologic, and/or nucleic acid probe technologies for detecting microbial agents and/or expressed gene products in tissue specimens or tissue culture; 3) conducting basic and applied research into the pathogenesis of infectious diseases; and 4) providing molecular pathology, histopathology, and ultrastructure reference/diagnostic support and epidemic aid to state and local health departments, other federal agencies, and national and international health

Three laboratory sections make up IDPA: Histology, Electron Microscopy, and Molecular Biology.

Histology occupies four laboratories which are well equipped with an automated H&E stainer, three immunostainers, an automated coverslipper, as well as several models of modern microtomes. Additionally, an inventory of over 500 antibodies to infectious agents makes histology well equipped for its diagnostic and research roles. Most of these antibodies are produced at CDC or in other government laboratories.

The electron microscopy laboratories utilize four transmission electron microscopes to perform thin section EM, immunocytochemistry, and *in situ* hybridization studies. Viral negative staining is used for outbreaks of gastrointestinal infections, which occur many times each week in cafeterias, restaurants, and cruise ships, among others.

Molecular biology technology is used extensively in all laboratories at NCID and is changing the way we approach the diagnosis of infectious diseases. Microbial DNA or RNA is extracted and sequenced, and the information used to develop custom polymerase chain reaction (PCR) primers and *in situ* hybridization (ISH) probes. PCR primers are used to detect and amplify specific sequences of DNA or RNA in tissue samples, and to make longer molecules to use as ISH probes. We are building an extensive library of PCR primers and ISH probes for microbe identification. Molecular biology in IDPA consists of two labs (and is growing) with all the equipment necessary to produce primers and probes and to maintain bacterial cultures for libraries. A semi-automated ISH routine is performed using the BioGenex OptiMax® stainer. A recent addition is a DNA sequencer.

IDPA also has extensive digital imaging and computer graphics capabilities. A Zeiss digital camera is used to capture microscopy images, and a Macintosh G4 computer is used to edit images for archives, publications, and web pages. In 2001, a confocal microscopy laboratory will be installed.

The normal workday involves diagnostic cases in which a cause of disease cannot be identified but an infectious disease is suspected. The majority of the work, however, is on long-term projects involving both human patient samples and animal models.

Outbreaks of infectious disease always cause a furious work pace; we need to diagnose the disease, determine how it is being transmitted, and how pathogenesis occurs as fast as possible to provide information to stop the outbreak and help patient treatment. Night and weekend work is common during outbreaks. In the last few years, several interesting outbreaks have shown that infectious disease is still

something to be concerned about as the following examples illustrate.

Hantavirus Pulmonary Syndrome (HPS). In the spring of 1993, many previously healthy people in the Four Corners area of the southwest US developed respiratory disease that was not explained by influenza or any other infectious disease then known. A large team from the CDC went to the area and collected many samples of human and animal tissues. Serology testing proved them to be infected with a Hantaan-type virus. This virus was at that time known only in Asia and had been seen in soldiers in the Korean war (presenting as kidney disease, however). Field mice turned out to be the host species and people were being exposed to the virus through aerosolized feces and urine of mice who had taken up warm quarters in their houses for the winter. Subsequent research has shown that Hanta viruses are found worldwide. IDPA determined the pathogenesis of the new disease.

Avian Influenza. In December of 1997, some people in Hong Kong showed signs of influenza infection. The strain of flu was not one ever seen in humans, however, and great effort was spent to find out what it was and where it came from. It was determined that the strain was one commonly found in chickens, and that it had been passed directly to humans—a first. Many people who lived near live chicken shops (very common in Hong Kong), or handled live chickens (again, very common), were infected with the virus. Several people died and several million chickens were destroyed in order to stop the outbreak. IDPA has been involved in studies to determine the pathogenicity and pathogenesis of several sub-strains of this virus.

Leptospirosis. In the fall of 1995, more than 2,000 people in northern Nicaragua contracted an acute febrile syndrome with fevers, chills, headaches, and musculoskeletal pain. The most severely ill patients had severe abdominal pain, hypotension,

respiratory insufficiency, and hemoptysis. Because of the indications of hemorrhagic fever, initial speculation centered on dengue hemorrhagic fever. However, testing by CDC ruled this out and IDPA testing proved leptospirosis to be the culprit.



In the summer of 1997, a triathlon was held in Illinois. Several days later many of the contestants became ill and some were hospitalized. It was determined by serology and immunopathology to be leptospirosis. In two cases that had tested negative, gallbladder tissues examined by IDPA showed infection with *Leptospira*. It was also found in the lake the triathletes swam in.

Nipah Virus. In the summer of 1998, pig farmers in Malaysia began exhibiting encephalitis and some died. Their pigs showed signs of respiratory problems. Initial speculation focused on endemic Japanese encephalitis (JE) but several factors ruled that out. It was primarily seen in male pig farmers who worked with sick pigs. Also, most of these people had been vaccinated for JE. Testing at CDC showed the virus to be a newly discovered paramyxovirus related to the Hendra virus found only two years previously in Australia. It was named Nipah virus after the district in which it was discovered. Over 100 people died and nearly a million pigs were destroyed to stop the outbreak. The IDPA was instrumental in determining the identity of the new virus, examining hundreds of tissue blocks to determine its pathogenesis.

We also developed new ISH tests within weeks of receiving specimens, using probes developed from viral genomic sequences determined in another lab at the CDC.

West Nile Virus. During the late summer of 1999, a few older people in New York City began showing up at hospitals with signs of encephalitis. At the same time a veterinarian at the Bronx Zoo noticed die-offs of certain birds, especially crows. Human tissues examined at IDPA indicated infection with St. Louis Encephalitis virus. Other CDC laboratories confirmed that result, and control measures for the mosquito vector of that virus began. A few days later, further testing at CDC laboratories found that the virus was actually a variant of West Nile virus, a relative of St. Louis Encephalitis virus, which had previously been found only in Africa, the Middle East, and Eastern Europe. This virus had never been seen in the Western Hemisphere and

many studies are underway to elucidate how it got here.

Ebola Hemorrhagic Fever. The Ebola virus shows itself rarely but when it does everyone pays attention, due to the high mortality (up to 90%), and gruesome effects of infection. While testing samples from the 1995 outbreak in Zaire, observations and experiments at IDPA led to the use of skin snips to detect the virus in living patients. Ebola attacks the endothelial cells of the blood vessels, which leads to the extensive bleeding seen in infected patients. IDPA observed that vessels in the skin of infected individuals had large amounts of viral antigen, and that skin biopsies were very reliable for diagnosing the disease. The use of skin samples makes collection and transport easy since they can be fixed, rather than frozen, as is the case with serum samples. This technique has been used in all outbreaks since, to easily and rapidly test for Ebola infection.

Not All Eosins Are Created Equal

Vinnie Della Speranza
Scientific Editor

Recently one of our staff was making up Eosin Y stain solution when I overheard her complaining that the solution "didn't look right." I noticed that the solution was a light orange color, instead of the dark rose color one expects from this dye. It appeared that she had done everything properly to make the solution. However, upon closer inspection I could see that most of the dye salt had not dissolved but was suspended in solution on the stir plate. This was an important clue since Eosin Y typically dissolves quite readily.



The dye powder that was used to make the solution was labeled Eosin yellowish (free acid), but it was an orange color, not the rust brown color we associate with Eosin Y. Someone had previously written "Eosin Y" on the bottle's label. Staining methods require the use of the disodium salt of Eosin Y ($C_{20}H_6Br_4Na_2O_5$ molecular wt. 691.88). While both forms may be listed in your chemical catalogue with the same color index number, it is important to be aware that the free acid form ($C_{20}H_8Br_4O_5$ molecular wt. 647.92) is highly insoluble in water (0.8 mg/ml)¹ unlike the disodium salt (40 mg/ml), which accounts for the unexpected color we obtained. Avoid buying Eosin Y free acid as it will not be useful to you in your lab.

Reference:

1. Green, FJ. *The Sigma-Aldrich Handbook of Stains, Dyes and Indicators*. Milwaukee, Wis: Aldrich Chemical Co.; 1990:304-306.

New Histotechnician Program

Earn your Associate in Science Degree
in Histotechnology

at Mt. San Antonio College in Southern California
Only program of its kind on the West Coast

Graduates, following internship, will be eligible for ASCP certification. Program includes immunohistochemistry and *in situ* hybridization.

First-year classes begin August 13, 2001

Affordable tuition: \$11 per unit
for California residents

For more information:

<http://histotech.mtsac.edu>

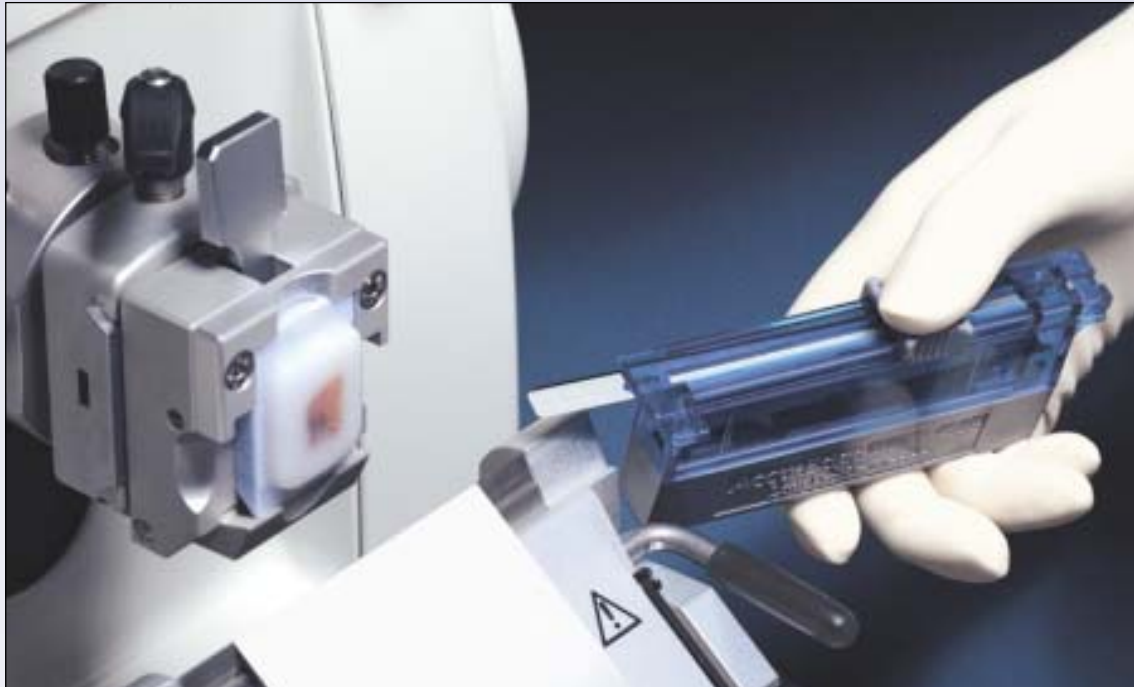or contact Jennifer MacDonald

at (909) 594-5611, ext. 4884

or by e-mail at jmacdona@mtsac.edu

This project was supported in part by the NATIONAL SCIENCE FOUNDATION. Opinions expressed are those of the authors and not necessarily those of the Foundation.

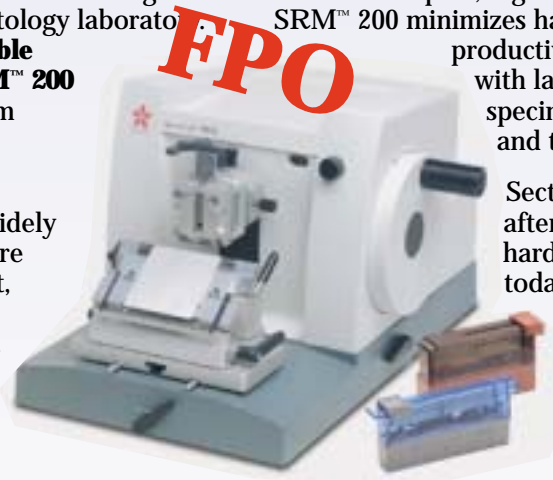Finally, a microtome that meets the quality of the Accu-Edge® blade.



Meet two partners well-equipped for the high-volume demands of today's histology laboratory. Together, **Accu-Edge® Disposable Blades** and the **Accu-Cut® SRM™ 200 Rotary Microtome** — both from **Tissue-Tek®** — create the ideal sectioning system.

Accu-Edge® blades, the most widely used blades for over 20 years, are ultrasharp, uniformly consistent, and undisputed in quality — virtually eliminating chattering, distortion, and striation.

With its compact, ergonomic design, the Accu-Cut® SRM™ 200 minimizes hand stress and optimizes productivity. (And comes complete with lateral displacement, specimen orientation, retraction, and trimming.)



Section after section, ribbon after ribbon, rely on the hardest-working partners in today's histology laboratory. Contact your Sakura sales representative today. Call 1-800-725-8723. Don't delay.

The perfect partners for precision sectioning.

Proven Reliability

Visit our web site at
www.sakuraus.com



Sakura Finetek U.S.A., Inc.
1750 West 214th Street
Torrance, CA 90501 U.S.A.
Phone: (800) 725-8723

Sakura

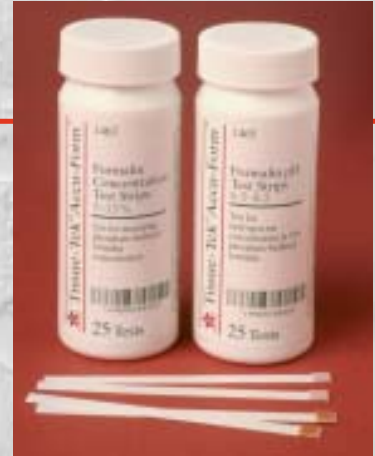Tissue-Tek® Accu-Form™

Formalin Concentration and Formalin pH Test Strips

The easiest tests you'll ever take.

Simple, quick, convenient

- Rapidly measure formalin concentration and formalin pH when preparing 10% NBF solutions, verifying ready-made solutions, or monitoring solutions in tissue processors
- Results in less than 2 minutes
- Proven color strip technology referenced to standard methods
- Easy-to-read color comparison charts ensure correct solution preparation
- Log sheets for maintaining proper Quality Assurance Program
- Packaged in two bottles of 25 strips each to avoid waste
- No instrumentation required



Sakura Finetek U.S.A., Inc.
1750 West 214th Street
Torrance, CA 90501 U.S.A.
Phone: (800) 725-8723

Proven Reliability

©2001 Sakura Finetek U.S.A., Inc.

Visit our web site at www.sakuraus.com

To receive your own copy of *HistoLogic*® or to have someone added to the mailing list, submit home address to: Sakura Finetek U.S.A., Inc., 1750 West 214th Street, Torrance, CA 90501.

The editor wishes to solicit information, questions, and articles relating to histotechnology. Submit these to: Vinnie Della Speranza, *HistoLogic*® Editor, 165 Ashley Avenue, Suite 309, Charleston, SC 29425. Articles, photographs, etc. will not be returned unless requested in writing when they are submitted.



Sakura Finetek U.S.A., Inc.
1750 West 214th Street
Torrance, California 90501

PRSRST STD
U.S. POSTAGE
PAID
TAMPA, FL
PERMIT NO. 2407

HISTOLOGIC®
Technical Bulletin for Histotechnology